

Castration of male calves

Male dairy calves and other young male livestock are castrated for a number of reasons. The farmer may want to prevent unwanted pregnancies on his farm, especially where livestock run in one herd. Bulls that have not been castrated, also tend to fight. They hurt each other and can cause damage to your fences and facilities. Castration can be done at any age, but preferably before the male animal is 12 months old. The best time is before the male calf is two months old.

Knife or open wound castration

This type of castration is regarded as a safe method, but hygiene is very important. The lower part of the scrotal sack is cut off and each testicle is removed by cutting the membrane that encloses the testicle. The spermatic cord and arteries are cut off through a scraping action, by holding the knife at an angle and scraping a few centimetres until the cord breaks. This causes less bleeding. If there is too much bleeding, the spermatic arteries can be tied off. Remember that this method removes the testicles completely and cannot be reversed.


Elastrator rings

A rubber ring is tied around the neck of the scrotal sack with a special instrument designed to do the tying. The testicles must be tied away from the body, towards the elastrator ring. After some time, the testicles and the tied back section of scrotal sack will degenerate and fall off. This method can be used on calves between birth and ten days of age. The calf is handled easily and little labour is involved. The method is bloodless. However, at this young age, the testicles might still not be visible.

Burdizzo or bloodless castration

A burdizzo is an instrument used to cut off the blood supply to the testicles. This causes death in the tissue cells and a degeneration of the testicles. The best time to apply this method, is at approximately one month old, when the spermatic cord can be clearly felt. The cord is clipped between the blades of the burdizzo. Clip only one cord at a time. The method is bloodless and there is seldom any infection. However, it does not work very well in older animals and requires two persons to do the job.

Wound care

- Watch cattle closely for about ten days after castration.
- Beware of blowfly attacks and infection, especially if you are applying the open wound method.
- Treat the wounds with an antibiotic powder and fly repellent.
- If the swelling and pain are severe, and if the animal develops a temperature, ask your veterinarian for help. He or she will probably inject the calf with a suitable antibiotic. 

Castration / Kastrasie / Ukuthenwa / Ukuyithena / Ho faholwa

Burdizzo

- The burdizzo cuts off the blood supply to the testicles.
- Apply when the calf is one month old.

Kastreertang (burdizzo)

- Die kastreertang sny die bloedtoevoer na die testikels af.
- Gebruik metode wanneer die kalf een maand oud is.

I-burdizzo

- Imatshini zokusika zisika izithumeli zegazi oluya ematapileni.
- Yenze xa ithole linyanga enye ubudala.

I-burdizzo

- I-burdizzo inqamula ukuya kwegazi emasendeni.
- Yenze lapho inkonyane linyanga eyodwa ubudala.

Burdizzo

- Burdizzo e kgina phephelo ya madi makwalateng.
- Etsa hona ha namane e le boholo ba kwedi.



Elastrator rings

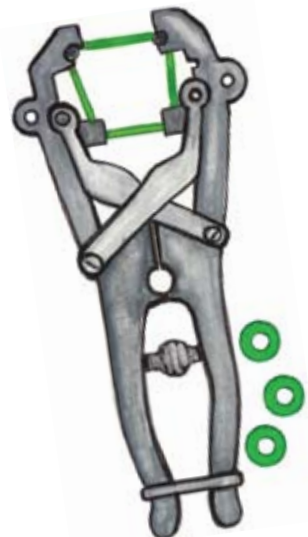
- Elastrator rings are tied around the neck of the scrotal sack.
- Use this method on calves between birth and ten days of age.

Rubber ringetjies

- Rubber ringetjies word om die nek van die skrotum gebind.
- Gebruik hierdie metode op kalfies tussen geboorte en 10 dae oud.

Imisesane ye-Elastrator

- Imisesane ye-elastrator zithandelwa entanyeni yesingxobo samasende.
- Sebenzisa le ndlela kumathole phakathi kokuzalwa kunye neentsuku ezilishumi ubudala.



Izintanjana zenjoloba

- Izintanjana zenjoloba ziboshelwa zizungeze isikhwama samasende.
- Sebenzisa le ndlela emankonyaneni kusukela lapho ezalwa aze abe nezinsuku eziyishumi ubudala.

Di-ring tsa Elastrator

- Di-ring tsa Elastrator di tlangwa molaleng wa mokotla wa makwalata.
- Sebedisa mोगwa ona manamaneng a pakeng tsa tswalo le matsatsi a leshome ka boholo.

Open wound castration

- Scrotal sack is cut off.
- Spermatic cord and arteries are scraped off.
- Treat wounds with antibiotic powder and fly repellent.

Oop kastrasio

- Die skrotum word afgesny.
- Die saadstring en are word afgeskraap.
- Behandel die wonde met antibiotiese poeier en vliegafweerder.

Vula isilonda sokuthenwa

- Isingxobo samatapile siyasikwa.
- Umbhobho wenzala kunye nonothumela begazi bayasikwa.
- Nyanga izilonda ngomgubo wokubulala iintsholongwane kunye nezinambuzane ezibhabhayo.

Ukuthena okuvula inxeba

- Isikhwama samasende siyanqunywa.
- Intanjana nemithambo yesidoda iyasuswa.
- Yelapha izilonda ngempushana elwa namagciwane kanye nomuthi oxosha nezimpukane.

Ho faholwa ho nang le leqeba le bulehileng

- Mokotla wa makwalata wa kgaolwa.
- Motjha wa lero la botona le di-athari di a sehwa.
- Hlwekisa maqeba ka phoho ya antibiotic le setebela-dintsintsi. 